

Robotic Follicular Unit Extraction in Hair Transplantation

MARC R. AVRAM, MD,* AND SHANNON A. WATKINS, MD†

BACKGROUND In recent years, there has been a shift toward minimally invasive procedures. In hair transplantation surgery, this trend has manifested with the emergence of follicular unit extraction (FUE). Recently, a robot has been introduced for FUE procedures.

OBJECTIVE To determine the transection rate of a robotic FUE device.

MATERIALS AND METHODS The authors discuss the procedure, technical requirements, optimal candidates, advantages, and disadvantages of robotic FUE compared with the standard ellipse.

RESULTS Optimal candidates for robotic FUE are those with dark hair color who can sit for 45 to 120 minutes and are willing to shave a large area for donor harvesting. The main advantages of robotic FUE compared with the standard ellipse are its minimally invasive nature and the lack of a linear scar. The average transection rate with the robot to date is 6.6% (range, 0.4%–32.1%).

CONCLUSION The robot is a new and innovative method for FUE hair transplantation of which hair transplant surgeons should be aware.

The authors have indicated no significant interest with commercial supporters.

In the 1990s, hair transplant surgery underwent a revolution in the graft size used for transplantation. From the 1960s into the mid 1990s, 2 to 4 mm grafts containing 10 to 20 hair follicles were the standard graft used in the procedure. In spite of its scientific success, they were often a cosmetic failure because they resulted in a “pluggy” unnatural appearance. In the 1990s, there was a shift toward smaller graft sizes. Currently, the follicular unit, which contains 1 to 4 hair follicles, is the standard graft size used in transplant surgery.^{1,2} This shift in graft size has allowed patients to consistently grow naturally appearing transplanted hair, as it mimics the natural size of follicular groupings on the scalp¹ (Figure 1). In addition, the use of follicular groupings eliminates textural changes and scarring in the recipient area. Large grafts containing 10 to 20 hair follicles required larger recipient sites, which resulted in unnatural “cobblestone” scarring on the scalp. Recipient sites for follicular groupings are less than

1 mm in diameter and create no visible scarring in the recipient zone of the scalp.¹

In the era of follicular unit transplantation, the only visible scar on the scalp is the linear scar left from the donor ellipse. For the majority of men and women, a linear scar in the posterior scalp has no short or long-term practical effect. Their existing donor hair will camouflage the scar. A linear scar can create an issue, however, for some patients who wear their hair shorter or want the option of a shorter hairstyle in the future. In addition, there has been an inexorable trend in all surgical procedures toward minimally invasive procedures, which result in less scarring and quicker recovery times.

Donor Harvesting Techniques

Over the past several years, the focus of discussion in the field has begun to shift away from the size of the

*Department of Dermatology, Weill Cornell Medical Center, New York, New York; †Private Practice, New York, New York

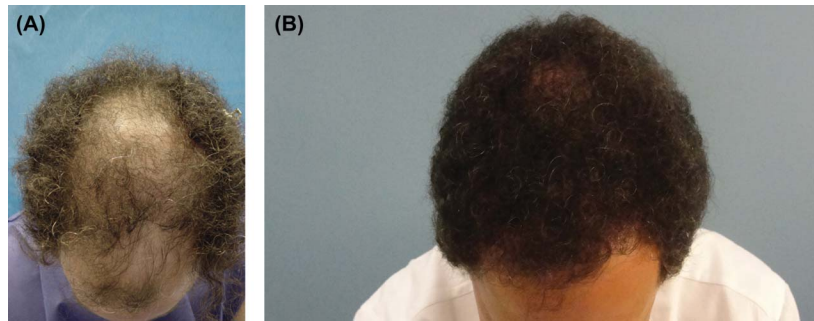


Figure 1. The same patient before (A) and after (B) hair transplantation, in whom 1,900 grafts in total were transplanted.

graft used to transplant hair toward the harvesting method used to obtain the donor grafts. For decades, 2 to 4 mm punch trephines were used to obtain donor hair from the posterior scalp. Typically, the grafts were removed and wounds were allowed to heal by secondary intention. This resulted in widespread “honeycomb” scarring (Figure 2). In 1994, the concept of elliptical donor harvesting, also known as strip harvesting, was introduced and has been the standard method for obtaining donor grafts.³ It is based on the same dermatologic surgery techniques used in removing nevi, skin carcinomas, and cysts. It allows efficient harvesting of hundreds to thousands of follicular groupings. As with any cutaneous excision, there is a scar created from removing the donor ellipse. For the majority of patients, this is neither a medical nor a cosmetic issue. For a minority of patients, medical and cosmetic challenges may arise. A small percentage of patients will develop hypertrophic or broad scars. Others feel limited in the hair styling options because of the donor scar. For these

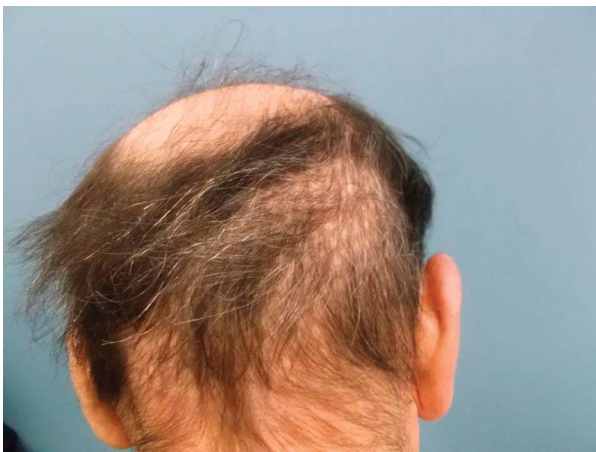

Figure 2. Honeycomb scarring.

reasons, and because of the general trend toward less-invasive procedures in medicine, alternate donor harvesting methods were investigated.

Follicular Unit Extraction Versus Elliptical Donor Harvesting

The concept of follicular unit extraction (FUE) was introduced in the early 21st century and refined over the past decade.^{4–6} Follicular unit extraction used the same concept of using a steel trephine to harvest donor hair, but instead of being 2 to 4 mm in diameter as was used in the past, the FUE punches range from 0.8 mm to 1.2 mm. This technique is a natural extension of the concept of follicular unit hair transplantation—the utilization of individual follicular groupings in the recipient *and* donor sites.

Challenges of this technique include the following: increased risk of transection of hair follicles, operator fatigue when harvesting hundreds of follicular groupings, and appropriate spacing of harvested grafts to yield the maximum amount of donor hair without creating the appearance of a depleted donor density.⁶ Throughout the posterior scalp, the angle of hair growth varies, which presents a challenge to surgeons. Magnification and excellent lighting reduce but do not eliminate the risk of transecting follicles. Compounding this challenge is the need to remove dozens to many hundreds of follicular groupings for each case. Harvesting larger numbers of grafts can result in increased operator fatigue and a higher rate of transected hair follicles. Some experienced surgeons are able to harvest large numbers of follicular groupings with minimal transections, but others are unable to do so.

To improve the accuracy and efficiency of FUE, numerous FUE devices have been developed; of which some are motorized, some are suction assisted, and some are single user-directed robotic system. The NeoGraft automated hair transplant system,⁷⁻⁹ SAFE (surgically advanced follicular extraction) system,¹⁰ and ARTAS Robotic System (Restoration Robotics, Inc, San Jose, CA) are a few of the more well-known FUE devices on the market. In this article, the authors discuss about robotic follicular unit extraction with the robot.

Robotic Follicular Unit Extraction

Technical Aspect

The robotic system was approved by the Food and Drug Administration for hair transplantation in 2011.¹¹ This robotic device is used to harvest follicular units from the donor region (Figure 3). A 1-mm punch is attached to the robotic arm consisting of a “needle-within-needle”; there is a sharp inner punch surrounded by a blunt outer punch. The sharp inner punch creates a shallow 1-mm incision, subsequently, the blunt outer punch spinning at 400 to 800 rpm dissects deeper and separates the follicular units from surrounding tissue. A suction system attached near the punch elevates the follicular unit from the surrounding skin allowing for easier extraction of the graft. A combination of stereoscopic cameras managed by image processing software allows the sharp and blunt punches to identify the precise angle and direction of hair growth. This continuous imaging feedback allows the robot to precisely harvest each follicular grouping. Because of the high level of automation, the robot is able to remove 400 to 600 grafts per hour.¹¹⁻¹³ The software requires a minimum distance of 1.6 mm between extracted follicular groupings to minimize the risk of overharvesting donor hair. In Table 1, the authors compare strip harvesting with robotic FUE for donor harvesting.

Procedure

Donor Region

Patients must trim their hair 1 to 1.5 mm in length for proper removal of follicular groupings whether

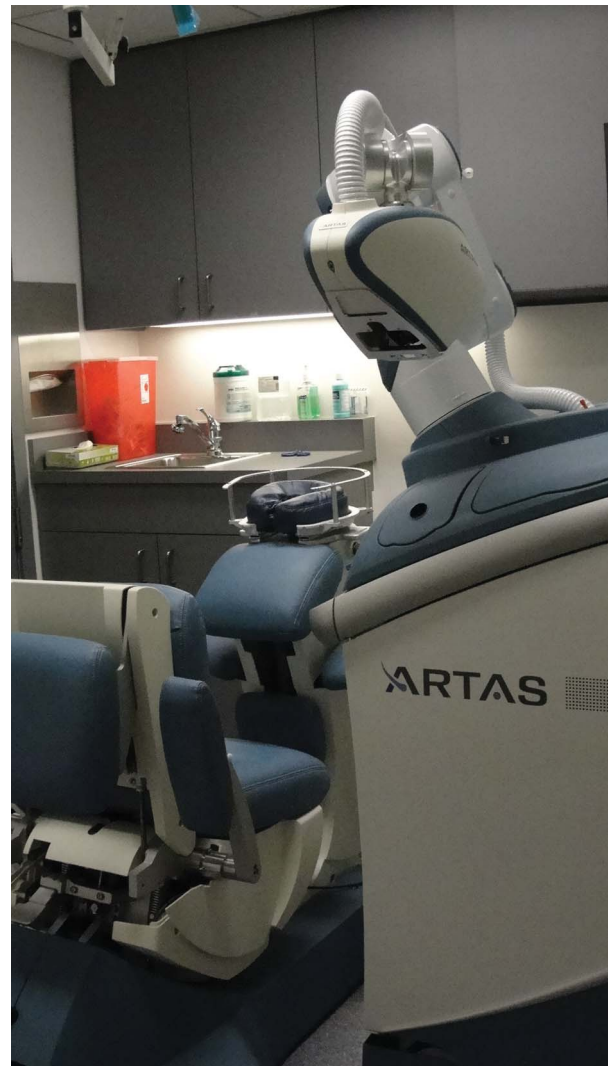

Figure 3. The robotic device.

performed using traditional manual punch FUE, a motorized FUE device, or robotic FUE. The area of trimming needed to harvest equal numbers of follicular groupings is *far greater* with traditional or robotic FUE than with a donor ellipse. This is of minimal practical concern for patients who can wear their hair shorter, but it is a major concern for those who wear their hair longer (Figure 4). In the authors' practice, all patients choosing robotic FUE to date have been men. No women have yet been willing to trim an extensive area of their posterior scalp for donor harvesting. The authors continue to prefer a donor ellipse for their hair transplant. In Table 2, they summarize the ideal qualities of a candidate undergoing robotic FUE.

TABLE 1. Comparison of Strip Harvesting to Robotic FUE Harvesting

	<i>Strip Harvesting</i>	<i>Robotic Follicular Unit Extraction</i>
Scarring	Linear scar	No linear scar
Time to harvest grafts	10–20 minutes for 300–2,000 grafts	45–60 minutes for 300–600 grafts; 60–120 minutes for 600–1,200 grafts
Healing time	7–10 days	3–5 days
Cost	Minimal	Significant to purchase machine (approximately \$240,000) and additional per surgery fee for each harvest attempt (approximately \$1/harvest attempt = attempt to extract 1 FUE)
Transaction rate	Low with experienced team; widely variable with inexperienced team	Low to low–moderate
Physician skill	Standard skin excision techniques	Knowledge of software program and robot
Technician skill	Skilled technician mandatory to create follicular units with low transection rate	Skilled technician needed to remove grafts from scalp and assess quality under magnification before placing in the recipient site
Reliability	Technician + physician dependent	Technician + physician + robot dependent
Area of donor site shaved	1.5 cm × 8–10 cm	4–8 cm × 10–20 cm
Space requirement	Can be done in office space used for standard excisions	Minimum office space: 10 foot × 10 foot; large procedural space Robot dimensions Cart: length 48 inches, width 27 inches, height 68 inches Chair: length 57 inches, width 33 inches, height 48 inches Weight: cart = 872 lbs, chair = 550 lbs
Electrical requirement	Power supply of a standard patient room	1. 208 VAC ± 10%, single phase, 50/60 Hz, 10 A. Required power outlet configuration is NEMA L6-20R twist lock
Technical requirements	None	1. Ethernet port, no Wi-Fi 2. Personal computer 3. Secondary monitor, with HDMI cables from robot to monitor 4. Desk (workstation), at least 2' x 3' working surface

VAC, volts of alternating current.

The sensors and cameras in the robot require pigment in the hair for optimal harvesting with minimal transection. Consequently, patients with blond, red, or gray hair have the donor hair dyed in the authors' office before administering local anesthesia. After

trimming, and dyeing if necessary, the donor region is anesthetized with local anesthesia. After anesthetizing the donor region, the patient finds a comfortable position in a chair specially designed for the robot. A skin tensioner measuring approximately 3 × 3 cm is

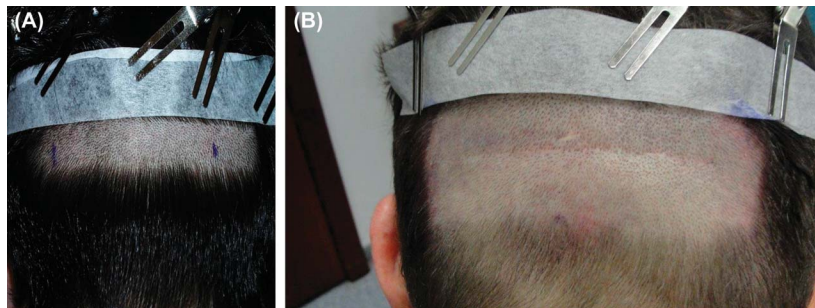


Figure 4. Donor region trim for strip harvesting (A) and for robot harvesting (B). Note that approximately the same number of hair follicles was transplanted in both cases.

TABLE 2. Robotic FUE Candidate Selection

	<i>Ideal Candidate</i>	<i>Suboptimal Candidate</i>
Area of donor site shaved	Willing to shave a large area for donor harvesting	Not willing to shave a large area for donor harvesting
Patient personality	Able to sit still for 45–120 minutes while grafts are harvested	Unable to sit still for long periods of time
Donor site density	High	Low*
Hair color	Brown, black hair	White, blonde, red hair†
Hair length	Short hair	Long hair
Patient's scar preference	A patient preferring no evidence of linear scar on their scalp after the procedure	A patient who does not mind a linear scar

*Note: more difficult to harvest large numbers of follicular units.

†Note this can be overcome by dyeing hair.

placed on the skin, which creates turgor necessary for optimal harvesting (Figure 5). The physician and assistant use a hand-held remote control and a computer monitor to control all aspects of the harvesting process. The spacing between harvests, needle depth, and the area to be harvested are controlled and adjusted if needed during the procedure. During the harvesting, the patient rests their head on a pillow similar to

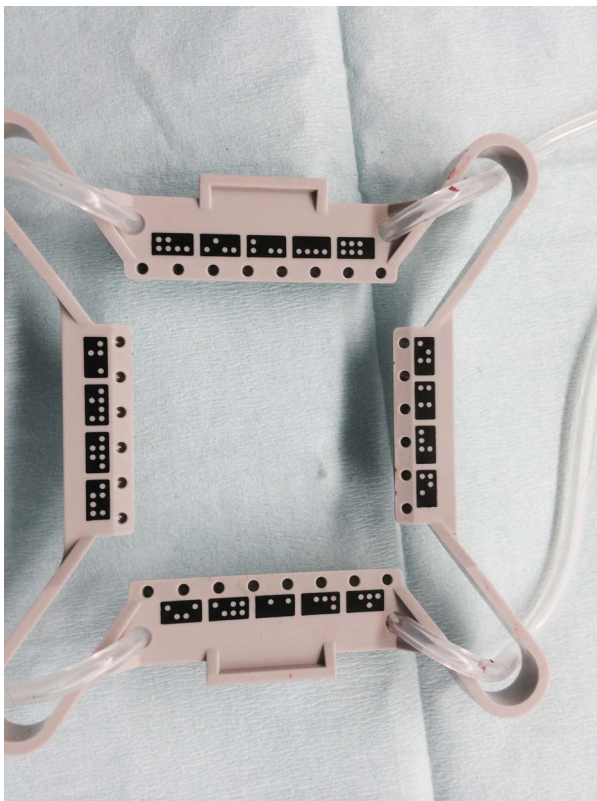


Figure 5. Skin tensioner for the robot.

that found on a massage chair. After each section is harvested, the physician moves the tensioner across the back of the scalp until the desired number of grafts is obtained. Each 3×3 cm tensioner harvests an average of 90 to 120 follicular groupings. Therefore, if a patient with an average density needs 800 grafts for the procedure, the tensioner will be moved 7 to 9 times across the donor region. While harvesting grafts, the robotic device displays the angle of hair growth, density of hair in the region, and counts the number of grafts obtained.

Once all the grafts are created, the robotic arm is retracted and the grafts are removed by technicians from the donor region using microvascular forceps. After the last graft is removed, a temporary dressing is applied and the patient can stand up, stretch, and get ready for the placement of the grafts into the recipient zone. The remainder of the procedure from hairline design to recipient site creation and graft placement is the same as with nonrobotic hair transplant surgery.

Processing of Grafts and Transection Rate

The grafts are kept in chilled saline and inspected under magnification. Each graft is inspected for damage to the follicular unit. In Table 3, there is a summary of the case-by-case transection rates noted over 20 consecutive robotic FUE cases. All 20 cases were performed by one operating physician and the same 3 hair transplant technicians. The ethnicity of the patients varied and included many races, including white, Asian, Middle Eastern, and Indian. The patients' hair colors included white, gray, black,

TABLE 3. Twenty Individual Case Statistics and Transection Rates

Patient	No. Grafts Harvested	No. Grafts Transected	Total Number Transplanted	Transection Rate (No. Grafts Transected/No. Grafts Harvested)
1	377	27	376	27/377 (7.2%)
2	236	1	241	1/236 (0.4%)
3	301	3	226	3/301 (1.0%)
4	550	4	599	4/550 (0.7%)
5	351	33	356	33/351 (9.4%)
6	223	1	234	1/223 (0.4%)
7	397	9	NA	9/397 (2.3%)
8	250	1	276	1/250 (0.4%)
9	477	30	623	30/477 (6.3%)
10	454	72	399	72/454 (15.9%)
11	358	28	384	28/258 (10.9%)
12	446	20	492	20/446 (4.5%)
13	430	30	492	30/430 (7.0%)
14	385	28	305	28/385 (7.3%)
15	206	5	212	5/206 (2.4%)
16	479	45	405	45/479 (9.4%)
17	536	52	545	52/536 (9.7%)
18	200	1	215	1/200 (0.5%)
19	504	20	598	20/504 (4.0%)
20	632	203	568	203/632 (32.1%)
Average	389.6	30.65	397.2	6.6%*

*Note: 6.6% is the mean of transection rates for each individual case. NA, not available.

brown, and blond hair, and all the patients had relatively straight hair. The grafts were evaluated by technicians with more than 15 years of experience each. Grafts noted to have more than 1 follicular grouping (often, 1 FUE graft may contain 3–4 hairs) were split into individual follicular groupings. It is not uncommon for 1 FUE to yield 2 grafts once split into follicular groupings. The total number of grafts harvested, grafts transected, and grafts transplanted were recorded. Grafts were counted as transected if any part of the hair follicle was missing (bulb, isthmus, or infundibulum). Capped hair follicles (hair follicles that had only the epidermis present) were also counted as transected. The transection rate ranged from 0.4% to 32.1%. The average transection rate was 6.6%. In the literature, strip harvesting using the “donor dissection” technique with an experienced hair transplant staff has been reported to have a 1.59% transection rate. In the “donor dissection” technique, direct visualization of hair follicles is used to minimize the transection rates.¹⁴ With traditional 0.8- to 1.2-mm

steel punch FUE or motorized FUE devices, there are some data regarding transection rates. One study by Onda and colleagues¹⁵ comparing the use of a novel powered FUE (P-FUE) device to manual FUE reported a 5.4% transection rate with P-FUE versus a 17.3% transection rate with manual FUE. Another study by Harris¹⁰ using the SAFE (Surgically Advanced Follicular Extraction) System reported an average transection rate of 6.14% with a range of 1.5% to 15%.

Discussion

Robotic FUE allows a physician to transplant many hundreds to thousands of follicular groupings from the donor region into the recipient area without creating a linear scar on the patient’s scalp. This is a major technical advance in the procedure. For years, manual and motorized FUE have been performed with success around the world. The challenge for many physicians with manual and motorized FUE is efficiently harvesting hundreds to thousands of follicular groupings with minimal transection. The

robot allows 400 to 600 follicular groupings to be harvested per hour with transection rates comparable with those of grafts created from an ellipse by experienced surgical assistants. There is no doubt that some physicians may be able to harvest large numbers of grafts using a manual punch or motorized device with transection rates similar to those of the robot. The expense, space requirements, and ongoing maintenance costs of a robot are not needed for these skilled physicians. Also, many physicians cannot efficiently harvest follicular groupings with low transection rates using manual or motorized FUE, and the robot will allow them to efficiently harvest high-quality grafts. The combination of stereoscopic cameras managed by image processing software allows the robot to accurately and efficiently harvest follicular units. Because of the high level of automation with the robot, there is a minimal learning curve compared with that of manual or motorized FUE. The robot also eliminates the issues of operator fatigue, which often results in higher transection rates with manual and motorized FUE. The robot is consistently able to remove 400 to 600 grafts per hour. Unfortunately, well-designed long-term studies comparing techniques such as the robot FUE to non-robotic FUE do not exist to date.

Currently, the robot is an additional option for donor harvesting. It has *not* replaced traditional elliptical donor harvesting or manual/motorized FUE. For patients who wear their hair short, want the option to wear it short, or simply do not want sutures or a linear scar on their scalp, robotic FUE is an efficient and safe method for harvesting follicular units. The authors report that the biggest practical hurdle for some of their patients has been the need to trim an extensive part of the donor region. To date, no women have opted for the robot, all have chosen the strip harvesting. Men have been evenly split between the ellipse and robot. The majority of men who have had an ellipse in the past have chosen an ellipse for repeat procedures because of high satisfaction with the previous result and the existing scar on their scalp. The majority of men who have not undergone a previous strip procedure have chosen robotic FUE to avoid sutures and a linear scar.

To date, the authors have had no known medical or surgical complications with any of their robot patients. Possible complications and side effects include a small risk of infection and bleeding, as with any surgical procedure. There will be pinpoint scars at the sites of follicular extraction. Additionally, proper spacing and removal of follicular groupings is necessary to reduce the risk of a “moth-eaten” or pseudo-syphilitic” appearance, and improper spacing can also result in necrosis, and cyst formation.^{16,17}

The authors have also found that the number of grafts harvested by the robot does not always directly correlate with the numbers of grafts transplanted. In some cases, higher transection rates have resulted in fewer grafts transplanted, whereas in other cases closely spaced follicular groupings within a 1-mm harvested graft have allowed more grafts to be placed than were harvested by the robot. As can be seen in Table 3, the transection rates of the 20 cases varied considerably, and ranged from 0.4% to 32.1%. In the authors’ experience, suboptimal tension and turgor when using the tensioner of the robot can lead to increased rates of transection. Careful placement of the tensioner and additional injection of saline for added turgor will reduce this risk. The authors did not notice any differences based on hair color or ethnicity. All patients reported by the authors had relatively straight hair. The authors suspect that in Case 20 with a 32.1% transection rate, suboptimal tension and turgor compounded with a “mushy dermis,” a term used to describe the characteristics of a dermis that lacks stiffness, may have contributed to the extraordinarily high transection rate.

Follicular unit extraction has expanded the number of patients eligible for a hair transplant procedure. In the past, younger patients in their twenties or early thirties who expressed a desire to wear their hair short or possibly wear their hair short in the future were not operated on because of the concern that a linear scar could present a problem in the future. Follicular unit extraction, by avoiding a linear scar, allows more diverse hair styling options for men undergoing the procedure. With FUE, if a patient opts to shave their hair, there should be no evidence of a hair transplant procedure. In addition, patients with extensive scarring

from large punch grafts and/or donor ellipse scars can benefit from FUE. The robot can harvest individual follicular groupings without creating another large full-thickness scar that may not heal well (Figure 6).

As with most technological advances, including contemporary dermatologic lasers and radiofrequency devices, the device comes with a considerable price tag, and a cost-benefit analysis should be performed for each practitioner before purchasing the device. Space is another concern in some practices because as the device occupies a considerable amount of space.

Future of Hair Transplantation

The era of robotic hair transplantation has begun. In the near future, the authors expect the robot to be able to harvest more grafts more rapidly and with even greater precision. They look forward to more data in the literature regarding experience of others with the robotic device. The current size of the tensioner (3×3 cm) mandates large areas of donor hair to be trimmed. The option of tensioners with different dimensions would allow greater flexibility in hair trimming and open the procedure to a greater number of patients.

Unfortunately, the authors anticipate complications from the robot as with any procedure. Hair transplantation is limited by the amount of donor hair available. Overzealous donor harvesting may create

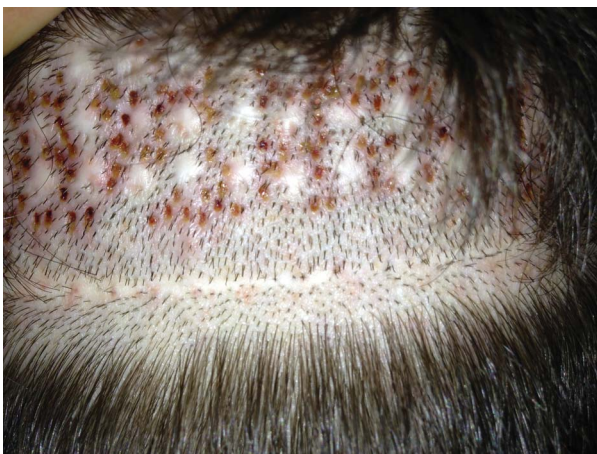

Figure 6. Robotic FUE in a patient with honeycomb scars from 3 to 4 mm punches and linear scars from the donor ellipse.

an iatrogenic pseudo-syphilitic appearance with “moth-eaten” donor regions. The robot’s software will not allow the machine to harvest hair closer than 1.6 mm during any one procedure. This ensures naturally appearing regrowth of hair in the donor region. Data regarding second and third procedures and the potential for thinning of the donor region do not exist. Until these data exist, a conservative approach to donor harvesting should be followed. Lack of a linear scar may also entice physicians to harvest hair from regions of future hair loss. This will result in the loss of those transplanted hairs in the future and relative thinning of transplanted hair in the frontal scalp. Additionally, follicular cysts have been described as a complication of other methods of FUE due to buried or subluxed grafts. They typically present 6 months—2 years after the FUE procedure.¹⁶ Theoretically, this same complication can result from robotic FUE, although the authors have not experienced these complications with the robot to date.

The ultimate goal of robotic hair transplantation is for the robot to perform donor harvesting, recipient site creation, *and* graft placement. Currently, robotic FUE harvesting requires less staff time to create follicular grafts than a strip harvesting. Robotic FUE directly produces follicular groupings, however a team of experienced surgical assistants is needed to process an ellipse into follicular units. An experienced team is still required to place grafts into the recipient sites, which precludes some physicians from performing the procedure. The ability of a robotic device to harvest grafts, create recipient sites, and place grafts, may dramatically increase the number of physicians who are capable of performing the procedure.

References

1. Whitworth JM, Stough DB, Limmer B, Limmer B, et al. A comparison of graft implantation techniques for hair transplantation. *Semin Cutan Med Surg* 1999;18:177–83.
2. Avram M, Rogers N. Contemporary hair transplantation. *Dermatol Surg* 2009;35:1705–19.
3. Limmer BL. Elliptical donor stereoscopically assisted micrografting as an approach to further refinement in hair transplantation. *J Dermatol Surg Oncol* 1994;20:789–93.
4. Rassman WR, Bernstein RM, McClellan R, Jones R, et al. Follicular unit extraction: minimally invasive surgery for hair transplantation. *Dermatol Surg* 2002;28:720–8.

5. Bernstein RM, Rassman WR. Follicular unit transplantation: 2005. *Dermatol Clin* 2005;23:393–414; v.
6. Harris JA. Follicular unit extraction. *Facial Plast Surg Clin North Am* 2013;21:375–84.
7. NeoGraft web site. Available from: <http://neograft.com/>. Accessed July 14, 2014.
8. Rose PT. The latest innovations in hair transplantation. *Facial Plast Surg* 2011;27:366–77.
9. Gupta A. Microrefined microfollicular hair transplant: a new modification in hair transplant. *Ann Plast Surg* 2014;73:257–65.
10. Harris JA. New methodology and instrumentation for follicular unit extraction: lower follicle transection rates and expanded patient candidacy. *Dermatol Surg* 2006;32:56–61; discussion 2.
11. Rose PT, Nusbaum B. Robotic hair restoration. *Dermatol Clin* 2014;32:97–107.
12. Harris J. Robotic-assisted follicular unit extraction for hair restoration: case reports. *Cosmet Dermatol* 2012;25:284–7.
13. Bernstein RM. Integrating robotic FUE into a hair transplant practice. *Hair Transplant Forum Intl* 2012;22:228–9.
14. Pathomvanich D. Donor harvesting: a new approach to minimize transection of hair follicles. *Dermatol Surg* 2000;26:345–8.
15. Onda M, Igawa HH, Inoue K, Tanino R. Novel technique of follicular unit extraction hair transplantation with a powered punching device. *Dermatol Surg* 2008;34:1683–8.
16. Poswal A, Bhutia S, Mehta R. When FUE goes wrong! *Indian J Dermatol* 2011;56:517–9.
17. Karacal N, Uraloglu M, Dindar T, Livaoglu M. Necrosis of the donor site after hair restoration with follicular unit extraction (FUE): a case report. *J Plast Reconstr Aesthet Surg* 2012;65:e87–9.

Address correspondence and reprint requests to: Marc R. Avram, MD, 905 Fifth Avenue, New York, NY 10021, or e-mail: mavram@dravram.com